

INTESTINAL EFFECTS OF SODIUM FLUORIDE IN SWISS ALBINO MICE

H Sondhi, M L Gupta and G L Gupta
Bikaner, India

SUMMARY: Adult Swiss Albino mice (6-7 weeks old) were treated with sodium fluoride (NaF) until autopsy. The organo-somatic index, histology and biochemistry of the intestines were observed at commencement of treatment and on the 7th, 15th and 30th day. The crypt cells exhibited cytoplasmic degranulation and vacuolation. Hydropic degeneration in lamina propria and muscular tissue, increase in the number of goblet cells, broken tips of villi, nuclear pyknosis, and abnormal mitoses were observed. The organo-somatic index decreased significantly on days 7 and 15. Total protein and cholesterol values declined significantly, whereas those of glycogen and acid, and alkaline phosphatase activities, increased significantly on day 7 and to day 30. The results provide evidence of intestinal involvement in fluorosis.

Key words: Intestinal effects; Sodium fluoride; Swiss albino mice.

Introduction

Fluoride in drinking water is easily absorbed by the intestines¹ and is quickly distributed throughout the body. Fluoride easily crosses membranes and enters tissues, thus affecting every phase of metabolism.² Bones and teeth especially are the sink for fluoride, which accumulates in them and causes fluorosis.³ Only limited work has been done, however, on the toxicity of fluoride on soft tissues, viz liver,⁴ kidney,⁵ muscles,⁶ and testes⁷. The aim of the present study, therefore, was to examine the effects of NaF in the intestines of Swiss albino mice.

Material and Methods

Twenty adult healthy Swiss albino mice (6-7 weeks old) were selected from our mice colony and treated as follows. The animals were fed mice feed and given sodium fluoride in water (100 ppm *ad libitum* until autopsy). Five mice were sacrificed by cervical dislocation on days 0, 7, 15, 30 from commencement of treatment. Three parameters were studied:

1. Organo-somatic index = $\frac{\text{weight of the organ} \times 100}{\text{total body weight}}$
(wt of liver/100 gm body wt)
2. Histological study: a piece of intestine was fixed in Bouin's fluid. After routine procedure 5-micron sections were cut and stained with haematoxylin and eosin.
3. Biochemical studies: the parameters estimated were total proteins,⁸ glycogen,⁹ cholesterol,¹⁰ and acid and alkaline phosphatase activities¹¹.

Results and Discussion

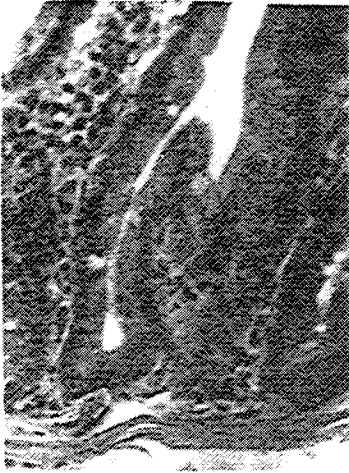The values of the organo-somatic index decreased significantly on day 7, continuing to day 15. The value increased by day 30, but it was still significantly lower than the 0-day value (Table 1). This decrease may be attributed to weight loss, degeneration of organs, and decreased protein levels. The functional sterility, with alterations in the structure, function, and metabolism of soft tissues in mice, rats, and rabbits administered different doses of fluoride has been observed.^{12,13}

Zoology Department, Dungar College, Bikaner 334 001, India.

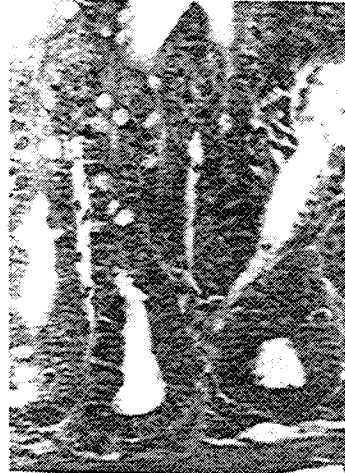TABLE 1. Changes in the values (mean \pm S.E.) of organo-somatic index (gm/100 gm of body weight) of intestine on Swiss albino mice after NaF treatment.

0 day	7 days	15 days	30 days
8.36 \pm 0.060	7.05 \pm 0.056	6.83 \pm 0.048	7.77 \pm 0.042
	P<0.001	P<0.001	P<0.001

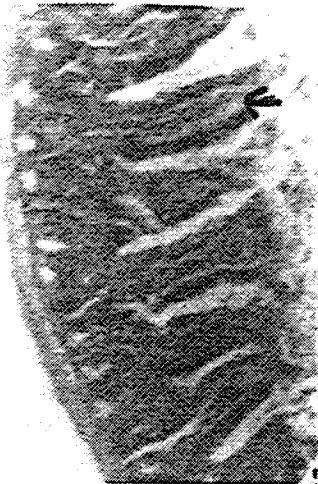Histopathological changes observed in intestine included increased numbers of goblet cells in the villi and in the crypts, loosened muscular part, cytoplasmic degranulation and vacuolation, nuclear pyknosis, and abnormal mitoses. Lymphocytic infiltration was widespread in sub-mucosa and lamina propria. The lesions were observed by day 7 and continued up to day 30, being severe by day 15 (see Figures 1-4 below, photomicrographs of intestines).



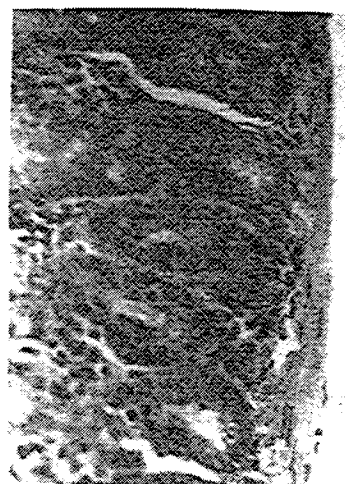
1. 0-Day. Almost normal structure. x 640



2. 7-day. Increased goblet cells, loosened muscular part, cytoplasmic changes. x 640



3. 15-day. Broken villi tips (arrow), cell debris in lumen. x 320



4. 30-day. Lymphocytic infiltration, cytoplasmic changes, nuclear pyknosis, abnormal mitoses. x 640

Biochemically significant decreases were noted in the values of total proteins, cholesterol from day 7 up to day 30, and increases in glycogen and acid and alkaline phosphatase activities from day 7 to day 30. Their values were significantly higher than the 0-day values (Table 2).

TABLE 2. Changes in the values (mean \pm S.E.) of biochemical parameters in intestine of Swiss albino mice after sodium fluoride treatment.

Biochemical parameters	0-day	7 days	15 days	30 days
Total proteins (mg/gm tissue weight)	95.32 \pm 1.23	91.23 \pm 1.26 P<0.05	84.20 \pm 1.85 P<0.01	79.45 \pm 2.23 P<0.001
Glycogen (mg/gm tissue weight)	0.96 \pm 0.011	1.16 \pm 0.010 P<0.001	1.54 \pm 0.012 P<0.001	1.83 \pm 0.12 P<0.001
Cholesterol (mg/gm tissue weight)	3.13 \pm 0.012	2.47 \pm 0.011 P<0.001	2.23 \pm 0.016 P<0.001	2.11 \pm 0.015 P<0.001
Acid Phosphatase Activity (mg pi/gm/hr)	1.86 \pm 0.032	2.36 \pm 0.045 P<0.001	2.85 \pm 0.036 P<0.001	3.13 \pm 0.052 P<0.001
Alkaline Phospha- tase Activity (mg pi/gm/hr)	22.36 \pm 0.21	26.54 \pm 0.23 P<0.001	30.36 \pm 0.34 P<0.001	32.67 \pm 0.27 P<0.001

Decreased total serum proteins in rabbits ingesting fluoride has been reported.¹⁴ Protein metabolism has also been shown to be affected by fluoride.¹⁵⁻¹⁷

After NaF treatment, an increase in glycogen values of muscle and liver has been observed.¹⁸ This may be attributed to reduced utilization of glycogen due to alteration in the activity of some key enzymes of carbohydrate metabolism.^{19,20} The *in vitro* and *in vivo* oxidation of fatty acids has been reported to be inhibited by fluorides.²¹ The increase in acid and alkaline phosphatase activities following NaF treatment may be due to disruption of lysosomes. Elevated plasma alkaline phosphatase and calcium levels have been found in endemic fluorosis areas.^{22,23} Gastro-intestinal manifestations are major features of intolerance to fluorides.²⁴

Acknowledgement

The authors are grateful to the Head, Zoology Department, and to the Principal, Dungar College, Bikaner, India, for their constant encouragement and for providing facilities.

References

- 1 Carlson CH, Armstrong WD, Singer LC. Distribution and excretion of radio-fluoride in the human. *Proceedings. Society for Experimental Biology and Medicine* 104 235-239 1960.
- 2 Zahvoronkov AA, Strochkova LS. Fluorosis: Geographical pathology and some experimental findings. *Fluoride* 14 (4) 182-191 1981.
- 3 Teotia SPS, Teotia M. Endemic fluoride. Bones and teeth update. *Indian Journal of Environmental Toxicology* 1 1-16 1991.
- 4 Kour K, Koul ML, Koul RL. Histological changes in liver following sodium fluoride ingestion. *Fluoride* 14 (3) 119-123 1981.

- 5 Kour K, Singh J. Histological findings in kidneys of mice following sodium fluoride administration. *Fluoride* 13 (4) 163-167 1980.
- 6 Shashi. Fluoride toxicity and muscular manifestations: Histopathological effects in rabbit. *Fluoride* 22 (2) 72-77 1989.
- 7 Kour K, Singh J. Histological finding of mice testes following fluoride ingestion. *Fluoride* 13 (4) 160-167 1980.
- 8 Lowry OH, Rosebrough NJ, Farr AL, Randall RJ. Protein measurement with the folin phenol reagent. *Journal of Biological Chemistry* 193 265-275 1951.
- 9 Montgomery R. Determination of glycogen. *Archives of Biochemistry and Biophysics* 67 378-386 1957.
- 10 Osler BL. *Hawk's Physiological Chemistry*. McGraw Hill, New York 1965 p 246.
- 11 Fiske CH, Subbarow Y. The colorimetric determination of phosphorus. *Journal of Biological Chemistry* 66 375-400 1925.
- 12 Chinoy NJ, Sequeira E. Effects of fluoride on histoarchitecture of reproductive organs of male mouse. *Reproductive Toxicology* 3 261-267 1989.
- 13 Chinoy NJ, Sequeira E. Fluoride induced biochemical changes in reproductive organs of male mice. *Fluoride* 22 (2) 78-85 1989.
- 14 Kaur R, Singh P, Makhni SS. Long term effects of fluoride administration - an experimental study (ii) Effect on serum proteins. *Fluoride* 11 (1) 25-28 1978.
- 15 Pandit CG, Naranyana, Rao D. Endemic fluorosis in South India Experimental production of Chronic fluorine intoxication in monkeys. *Indian Journal of Medical Research* 28 559-574 1940.
- 16 Vesco C, Colombo B. Effect of sodium fluoride on protein synthesis in the cells. Inhibition of ribosomes dissociation. *Journal of Molecular Biology* 47 335-352 1970.
- 17 Macuch P, Balazoa G, Bartosona L *et al*. Hygienic analysis of the influence of noxious factors on the environment and the state of health of the population in the vicinity of an aluminium plant. *Journal of Hygiene and Epidemiology* 7 389-403 1963.
- 18 Chinoy NJ, Sharma M, Michael M. Beneficial effects of ascorbic acid and calcium on reversal of fluoride toxicity in male rats. *Fluoride* 26 (1) 45-46 1993.
- 19 Carlson JR, Suttie JW. Pentose phosphate pathway enzymes and glucose oxidation in fluoride fed rats. *American Journal of Physiology* 210 79-83 1966.
- 20 Zebrowski EJ, Suttie JW, Phillips PH. Glucose oxidation and glycogen metabolism in fluoride fed rats. *Journal of Nutrition* 88 267-272 1966.
- 21 Jenkins GN, Venkateswarlu P, Zipkin I. Physiological effects of small doses of fluoride. In: *Fluorides and Human Health*. Monograph series No 59. World Health Organization, Geneva 1970 pp 163-224.
- 22 Teotia M, Teotia SPS. Hyperactivity of the parathyroid glands in endemic osteofluorosis. *Fluoride* 5 115-125 1972..
- 23 Teotia M, Teotia SPS. Skeletal fluoride toxicity in children. *Indian Journal of Pediatrics* 46 389-396 1979.
- 24 Susheela AK, Kumar A, Bhatnagar M, Bahadur R. Prevalence of endemic fluorosis with gastrointestinal manifestations in people living in some North-Indian villages. *Fluoride* 26 (2) 97-104 1993.