EFFECTS OF CHRONIC FLUOROSIS ON ELECTROCARDIOGRAM IN DOGS

D Kilicalp,[a] A Cinar,[b] F Belge[b]
Van, Turkey

SUMMARY: The aim of this study was to determine the effects of chronic fluorosis on the electrocardiogram (ECG) in dogs. A total of sixteen mixed breed dogs (8 fluorotic and 8 healthy), 2 to 3 years old and weighing 18–30 kg, were used in this study. The eight dogs with chronic fluorosis were obtained from the Tendurek Mountain region (altitude about 2000 m) in Eastern Anatolia. All ECG waves were observed in all of the leads. Sinus bradycardia was seen in dogs with chronic fluorosis. Prolonged P-Q interval (P<0.05) was present. The duration and amplitude of T wave was higher and longer (P<0.05) in the fluorosis group. As a result, the number of heart beats/minute was decreased significantly (p< 0.05) from 120.4±15 in the control group to 80.7±14 in dogs with fluorosis. The average electrical axis of the heart changes were between +60º and +100º in both groups. The average electrical axis was +80º in the control group and +75º in the fluorotic dogs.

Keywords: Bradycardia; Chronic fluorosis; Dogs; Electrocardiography (ECG).

INTRODUCTION

In recent years many medical workers have realized that fluoride accumulates not only in bones and teeth but, to a lesser extent, in soft tissues, especially the cardiovascular system.[1] Fluoride can rapidly cross the cell membrane and is distributed in skeletal and cardiac muscle, liver, skin and erythrocytes.[2-4] High concentrations of fluoride are noxious in the environment, affecting the health of humans and animals.[5] Volcanic sites in the world are rich in fluoride, and chronic fluorosis is found in such regions.[6,7]

Chronic fluorosis is endemic in parts of eastern Turkey for humans and animals. They consume fluoride from water near the volcanic area in Tendurek (altitude 3533 m). Natural water resources there are rich in fluoride, ranging from 5.7 to 15.2 ppm.[6,8] In the highest part of Eastern Anatolia in Turkey, Ergun *et al*[6] found 3787–5299 ppm fluoride in teeth, 17.4 ppm in soil, and 15.2 ppm in plants. Malformation of teeth and bones and disturbances in energy and carbohydrates metabolism have been widely observed in humans and animals living in this area.[9-11]

Although various effects of chronic fluorosis on different mechanisms have been examined,[1-3,10,11] its effect on the circulatory system has received only limited study. Therefore, in this investigation, we aimed to determine the

[a]For Correspondence: Dide Kilicalp, Department of Physiology, Faculty of Veterinary Medicine, Yuzuncu Yil University, Van 65080, Turkey; E-mail: dkilicalp@yahoo.com; [b]Dept. of Physiology, Faculty of Veterinary Medicine.

effects of chronic fluorosis on electrocardiogram (ECG) values and electrical axis of the heart in fluorotic dogs.

MATERIAL AND METHODS

A total of sixteen mixed breed dogs (8 fluorotic and 8 healthy) between 2 and 3 years of age, weighing 18–30 kg, were used in this study. These animals were street dogs and were not fed by us. Eight dogs with chronic fluorosis were obtained from the Tendurek Mountain region (altitude about 2000 m) in Eastern Anatolia. All were living in and around Tendurek Mountain (Ağrĩ, Turkey). Chronic fluorosis was determined after clinical examination of these dogs.[9] The eight healthy dogs used as the control group were obtained from the Van region (altitude 1700 m).

For the ECG study, the dogs were placed on a table in a right lateral recumbency position. The arm leads were placed just above the elbows, and the leg leads were placed just above the stifle joints. Electrode gel was rubbed into the skin in the area where the alligator clips were attached to act as a degreasing agent to decrease the electrical resistance of the skin. Alligator clips were attached to the skin at the left sixth intercostal space at the chondrosternal junction (CV_6LL, V_2), the sixth intercostal space at the costochondral junction (CV_6LU, V_4), and the dorsal spinous process of the seventh thoracic vertebra (V_{10}).[12] Readings were begun after about 10 min, when the dogs were calm. The dogs were not anesthetized at any time.

ECGs were recorded by a direct writing electrocardiograph (Cardiofax 6851; Nihon Kohden, Tokyo). All recordings were standardized at 1 mv = 10 mm, with a chart speed of 50 mm/sec. Leads I, II, III, aVR, aVL, aVF, and V_2, V_4, and V_{10} were recorded.[12] The durations and amplitudes of the waves on the trace were measured in lead II, and the electrical axis was also measured in leads II and III.[12] Statistical analyses were performed by using Student's t test.

RESULTS

Clinical examination of the dogs with chronic fluorosis revealed teeth that were abnormal in shape, size, color, orientation, and structure. The incisor teeth were pitted, and the molar teeth were abraded. Pulp cavities were also exposed to fracture or wear. Osseous lesions included exostoses of the jaw and long bones, usually accompanied by thickening and change of the bones. The dogs were lame and showed pain and difficulty when moving.

The durations and amplitudes of all waves are shown in the Table. The Figure shows the ECG of a healthy dog (A) and a fluorotic dog (B). All waves

were seen in all of the leads. Sinus bradycardia was observed in the eight dogs with chronic fluorosis. In these dogs there was a prolongation at the P-Q interval ($P<0.05$). The duration and amplitude of the T wave was also higher with greater peaking ($P<0.05$). The average electrical axis of the heart changes were between +60º and +100º in both groups. The average was +80º in the control group and +75º in the fluorotic group.

Table. Amplitudes and durations of waves and heart rate of lead II in age and weight-matched healthy and fluorotic dogs (mean ± SD)

Measured parameters	Control dogs (n=8)	Fluorotic dogs (n=8)
P (s)	0.04±0.00	0.04±0.00
P (mV)	0.10±0.00	0.20±0.00*
P-Q (s)	0.10±0.00	0.12±0.01
QRS (s)	0.06±0.02	0.06±0.00
QRS (mV)	1.10±0.01	0.60±0.02*
T (s)	0.04±0.00	0.14±0.00*
T (mV)	0.20±0.01	0.30±0.01*
Q-T (s)	0.22±0.02	0.20±0.01
Heart rate (beats/min)	120.4±15	80.7±14*
Electrical axis (degrees)	+80±5.50	+75±5.00

* $P<0.05$

DISCUSSION

Fluoride is known to cross cell membranes and to enter soft tissues. Various changes occur in blood, brain, and liver of animals after chronic administration of fluoride. These changes include abnormal behaviour patterns, altered neuronal and cerebrovascular integrity, and metabolic lesions. In animals, tenderness of long bone epiphyses, pareses, demineralization, hypermineralization, and bone fragility and brittleness have been observed. Apart from the relatively late anatomical lesions, fluoride is responsible for metabolic disorders in various systems, organs, tissues, and individual cells.[4,6-9] As a result, these disorders can affect the heart and the ECG.

In the present study the P wave that represents atrial depolarization was seen in all leads. The mean duration and amplitude of the P wave were 0.04±0.00 sec and 0.2±0.00 mV, respectively. The P-Q interval, which repre-

sents the time period from initiation of atrial depolarization to initiation of ventricular depolarization, was longer ($P<0.05$) in dogs with than without chronic fluorosis (Table and Figure A and B).

A

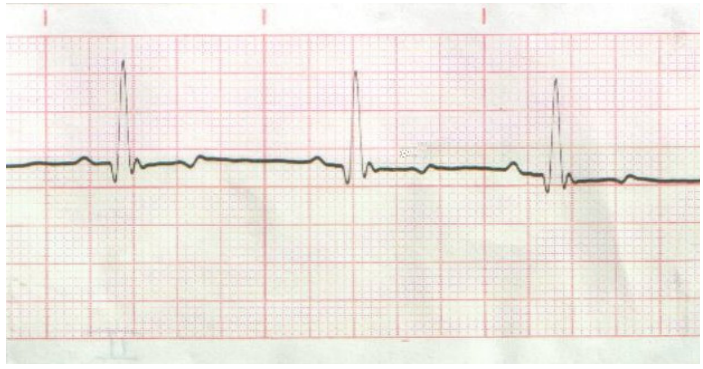

B

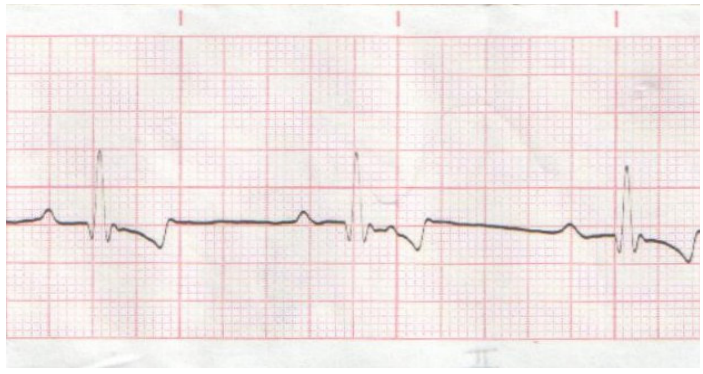

Figure. Electrocardiogram of a healthy dog (A) and of a fluorotic dog (B) with the later showing sinusoidal bradycardia (1 mV = 10 mm; chart speed = 50 mm/s).

In the fluorotic dogs the mean duration of the Q-T interval, which represents the time period from the onset of ventricular depolarization to the completion of ventricular repolarization, was 0.20±0.01 s, and the QRS complex that represents ventricular depolarization was 0.06±0.00 s. The mean amplitude of the QRS complex was almost the same as in the controls (Table). The mean duration and amplitude of the T wave that represents ventricular repolarization were higher and longer in dogs with chronic fluorosis (Figure B). This result may be due to a decrease in the level of blood potassium, which is

lowered in dogs subjected to excessive fluoride intake.[11] Shivashankara *et al*[13] reported that children with chronic fluorosis have reduced serum potassium and urea concentrations.

Abnormal ECG findings (sinus irregularity, sinus bradycardia, low voltage, ST and T wave changes) in patients with skeletal fluorosis were demonstrated by Xu *et al*.[1] Zhiliang *et al*[14] also found sinus arrhythmia and/or bradycardia, various conductive blocks, T wave changes, premature beats, and myocardial ischemias in metallurgical industry workers. In the present study the mean heart rate of the fluorotic dogs was 40 beats/min slower than in the healthy dogs. In agreement with other work,[1,14] sinusoidal bradycardia was also seen in the fluorotic dogs ($P<0.05$) (Table and Figure A and B). This effect in animals with chronic fluorosis could be due to insufficient synthesis and secretion of iodine and thyroid hormones. Bildik and Camas[8] investigated the effect of fluorosis on some specific liver enzymes and its correlation with iodine metabolism in sheep. They found an appreciable decrease in the level of protein bound iodine (PBI) and fluoride binding in blood. In another other study,[15] dysfunction of the thyroid gland in rats correlated with the level of fluoride intake, suggesting a high affinity of fluoride for the thyroid gland. Because of the high content of fluoride in the gland tissue, chronic fluorosis can cause a decrease in T_3 and T_4 hormone levels. A decrease in blood PBI and T_3 and T_4 produces a decrease in the rate of metabolism. In individuals with hypothyroidism the rate of metabolism decreases about 30–40 %.[16]

The sinusoidal bradycardia seen in the chronic fluorotic animals in this study may therefore be due to hypofunction of the thyroid gland. The role of thyroid hormones in all vertebrates is to accelerate oxidative functions. Guan *et al*[15] demonstrated that chronic fluoride intoxication caused severe morphological and functional changes in the thyroid gland of the rat. T_3 and T_4 control the speed of metabolism by facilitating cellular oxidation. The average value of the mean electrical axis, or net vector of electrical activity of the heart that represents the position of heart in the thoracic cavity are between +40º and +100º in dogs.[12] This means that in the fluorotic and the control dogs the heart is in a normal position in the thoracic cavity.

REFERENCES

1 Xu RY, Xu RQ. Electrocardiogram analysis of patients with skeletal fluorosis. Fluoride 1997;30(1):16-8.
2 Carlson CH, Armstrong WD, Singer L. Distribution and excretion of radio-fluoride in the human. Proc Soc Exp Biol 1960;104:235-9.
3 Jacyszyn K, Marut A. Fluoride in blood and urine in humans administered fluoride and exposed to fluoride-polluted air. Fluoride 1986;19(1):26-32.
4 Suska M. Energy metabolism of erythrocytes in lambs chronically exposed to fluorine compounds. Acta Vet Brno 2002;71:313-7.

5 Li J, Coa S. Recent studies on endemic fluorosis in China. Fluoride 1994;27(3):125-8.
6 Ergun H, Russel H, Baysu N, Dundar Y. Studies on the fluoride contents in water and soil urine, bone, and teeth of sheep and urine of humans from eastern and western parts of Turkey. Dtsch Tieraztl Wschr 1987;94:416-20.
7 Choubisa SL. Some observations on endemic fluorosis in domestic animals in Southern Rajasthan (India). Vet Res Com 1999;23(7):457-65.
8 Bildik A, Camas H. Research on some specific liver enzyme activities and PBI values in the blood serum of sheep with fluorosis. Kafkas Univ J Sciences 1996;1:16-23.
9 Underwood EJ. Trace Elements in Human and Animal Nutrition. 4th ed. New York: Academic Press Inc; 1977; p. 347-63.
10 Wang YN, Xiao KQ, Liu JL, Dallner G, Guan ZZ. Effect of long-term fluoride exposure on lipid composition in rat liver. Toxicology 2000;146(2-3):161-9.
11 Gaugl JF, Wooldridge B. Cardiopulmonary response to sodium fluoride infusion in the dog. J Toxicol Environ Health 1983;11(4-6):765-82.
12 Edwards NJ. Bolton's Handbook of Canine and Feline Electrocardiography. 2nd ed. W.B. Saunders Company; 1987.
13 Shivashankara AR, Shankara YMS, Rao SH, Bhat GP. A clinical and biochemical study of chronic fluoride toxicity in children of Kheru Thanda of Gulbarga District, Karnataka, India. Fluoride 2000;33(2):66-73.
14 Zhiliang Y, Yihua L, Liansheng Z, Zhengping Z. Industrial fluoride pollution in the metallurgical industry in China. Fluoride 1987;2093):118-25.
15 Guan ZZ, Zhuang ZJ, Yang PS, Pan S. Synergistic action of iodine deficiency and fluorine intoxication on rat thyroid. Chin Med J 1988;101(9):679-84.
16 Guyton AC. Textbook of Medical Physiology. 8th ed. W.B. Saunders Company; 1991.

Published by the International Society for Fluoride Research
http://homepages.ihug.co.nz/~spittle/fluoride-journal.htm
Editorial Office: 727 Brighton Road, Ocean View, Dunedin 9051, New Zealand